

Received: 2019.08.29  
Accepted: 2019.09.11  
Available online: 2020.01.24  
Published: 2020.02.01

## Clinical Management of Squamous Cell Carcinoma of the Conjunctiva

Authors' Contribution:  
Study Design A  
Data Collection B  
Statistical Analysis C  
Data Interpretation D  
Manuscript Preparation E  
Literature Search F  
Funds Collection G

ABCDEF 1 **Tobias Röck**  
ABCE 1 **Karl Ulrich Bartz-Schmidt**  
ABCDE 2 **Matthias Bramkamp**  
DE 3 **Jakob Milla**  
ABCDE 3 **Hans-Christian Bösmüller**  
ABCD 1 **Daniel Röck**

1 Department of Ophthalmology, Eberhard Karls University Tübingen, Tübingen, Germany  
2 Department of General Medicine, Ruhr-University Bochum, Bochum, Germany  
3 Institute of Pathology and Neuropathology, Eberhard Karls University Tübingen, Tübingen, Germany

**Corresponding Author:** Tobias Röck, e-mail: [Tobias.Roeck@med.uni-tuebingen.de](mailto:Tobias.Roeck@med.uni-tuebingen.de)  
**Conflict of interest:** None declared  
**Source of support:** Departmental sources





---

**Patient:** Female, 33-year-old  
**Final Diagnosis:** Conjunctival squamous cell carcinoma  
**Symptoms:** Tumorous lesion on the nasal bulbar conjunctiva • red eye  
**Medication:** —  
**Clinical Procedure:** The conjunctival tumor was excised. The histopathological diagnosis suggested a conjunctival squamous cell carcinoma. A treatment with topical MMC was administered  
**Specialty:** Ophthalmology

**Objective:** Rare disease  
**Background:** Conjunctival squamous cell carcinoma is the most common non-pigmented malignancy of the ocular surface. This report illustrates the clinical management of squamous cell carcinoma of the conjunctiva.  
**Case Report:** A 33-year-old female was referred to our eye hospital with a tumorous lesion on the nasal bulbar conjunctiva of the right eye. A topical therapy with antibiotic and corticosteroid eye drops did not change the lesion. The conjunctival tumor was widely resected. The histopathological diagnosis suggested a squamous cell carcinoma. After resection, a treatment with topical mitomycin C (MMC) 0.02% eye drops were started 4 times daily for 14 days. Two cycles of treatment were done with a 2-week interval during which only artificial tears eye drops were administered. At the 12-month follow-up, there was no sign of recurrence.  
**Conclusions:** This case illustrates the effective and successful clinical management of squamous cell carcinoma of the conjunctiva with excision and postoperative treatment with MMC 0.02% eye drops.

**MeSH Keywords:** Ambulatory Surgical Procedures • Antineoplastic Agents • Carcinoma, Squamous Cell

**Full-text PDF:** <https://www.amjcaserep.com/abstract/index/idArt/919751>

 1130  —  3  15



## Background

Conjunctival squamous cell carcinoma (SCC) is the most common non-pigmented malignancy of the ocular surface [1]. The incidence is about 9 to 10 times higher in the African population than in the Caucasian population [2,3]. SCC occurs usually within the exposed part of the eyeball between the lids in sun damaged conjunctiva at the limbus [4]. Therefore, the primary risk factor for SCC is ultraviolet B radiation. The gold standard for the diagnosis of SCC is histopathologic evaluation following an excisional biopsy. Invasive conjunctival SCC is commonly treated by excision with or without adjunctive cryotherapy [5]. After resection topical mitomycin C (MMC) seem to be a safe and effective therapy for conjunctival and corneal SCC, even when there is extensive recurrent tumor [6], however, in literature there is no consensus on the dose or duration of treatment [6–9].

Here, this report illustrates the case of SSC of the conjunctiva managed with excision and postoperative treatment with MMC 0.02% eye drops.

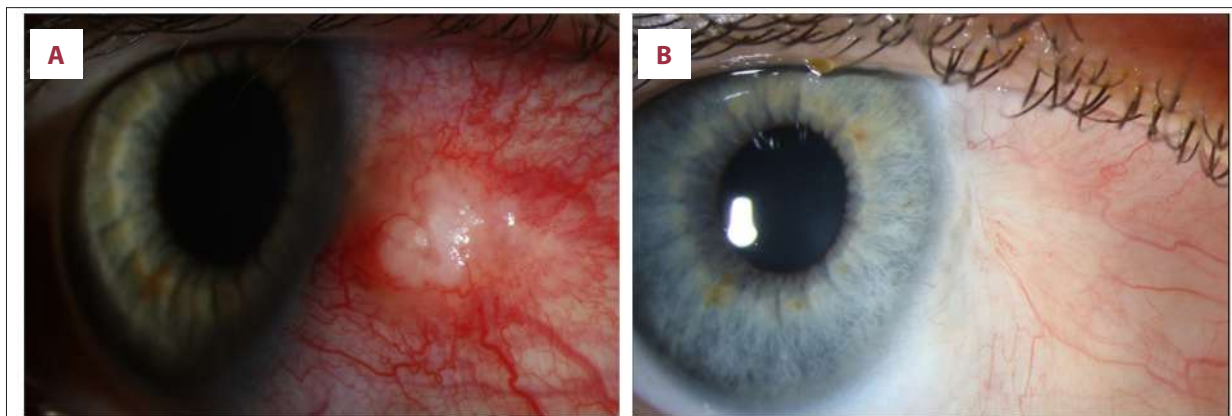
## Case Report

A 33-year-old female was referred to our eye hospital in April 2018 with a tumorous lesion (2.8×3.0 mm) on the nasal bulbar conjunctiva of the right eye. Upon examination, a gelatinous lesion and an inflammation was present on the nasal bulbar conjunctiva of the right eye (Figure 1A). The initial clinical findings showed a tumor, which appeared to be freely movable and a vascular rich surrounding inflammatory. A topical therapy with Maxitrol eye drops (Novartis Pharma Schweiz AG, Rotkreuz, Switzerland), a combination of corticosteroid and antibiotic eye drops (1 mL suspension contains 1 mg dexamethasone, 6000 IU polymyxin B sulphate, 3500 IU neomycin

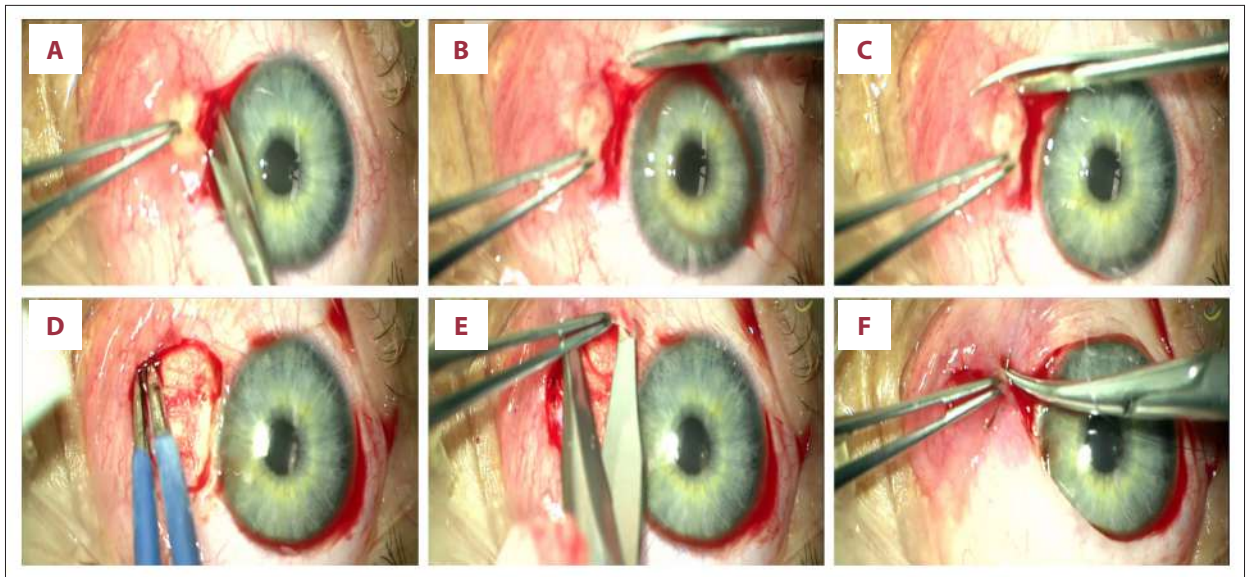
sulphate), and artificial tears have been used 4 times a day over a 2-week period before. The lesion did not change, even became larger in size. The conjunctival tumor was excised with Vannas scissors using a wide excisional biopsy with a tumor safety distance of at least 2.0 mm after application of topical anesthesia (5 drops of a single dose of 0.4% oxybuprocaine hydrochloride) and subconjunctival anesthesia with 2% mepivacaine. Cautery was gently applied to bleeding vessels. Then, the procedure of primary closure involved closure of the conjunctival defect following undermining and mobilization of the surrounding conjunctiva to cover the bare sclera. The conjunctiva was then sutured by 4 interrupted 9-0 Vicryl sutures. For this case the color photo documentation of the surgery steps is shown in Figure 2.

The histopathological diagnosis suggested SSC. After resection, a treatment with topical MMC (Alte Apotheke, Stuttgart, Germany) 0.02% eye drops were started 4 times daily for 14 days. Two cycles of treatment were done with a 2-week interval during which only artificial tears eye drops were administered.

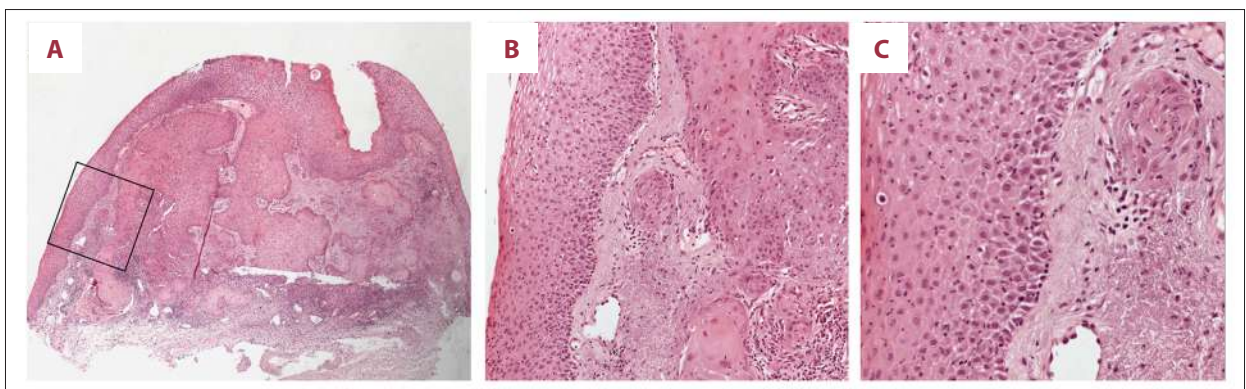
Additionally topical corticosteroid [1.3 mg/mL dexamethasone eye drops; (DexaEDO<sup>®</sup>, Bausch+Lomb GmbH, Dr. Gerhard Mann Chem.-pharm. Fabrik GmbH, Berlin, Germany)], antibiotic eye drops [0.5% moxifloxacin hydrochloride ophthalmic solution; (Vigamox<sup>®</sup>, Novartis Pharma GmbH, Nürnberg, Germany)], and artificial tears (Artelac<sup>®</sup> splash EDO, Bausch+Lomb GmbH, Dr. Gerhard Mann Chem.-Pharm. Fabrik GmbH, Berlin, Germany), were used postoperatively 4 times a day over a 2-week period. Then, the corticosteroid eye drops were reduced by 1 drop each week, while the artificial tears were still applied 4 times a day for 8 weeks. After the resection, surgical margins were diagnosed as tumor free by histopathological examination. A reduction in the inflammation and healing of the conjunctival lesion could be seen. At the 12-month follow-up a slit-lamp examination revealed no sign of recurrence (Figure 1B).



**Figure 1.** (A) Initial slit-lamp image showing a gelatinous, tumorous lesion and inflammation on the nasal bulbar conjunctiva of the right eye. (B) At the 12-month follow-up a slit-lamp examination revealed stable findings. There was no sign of recurrence or any postoperative complication (slit-lamp images with white light showing a 10× magnification).



**Figure 2.** Color photograph of the surgical video after the application of topical anesthesia (5 drops of a single dose of 0.4% oxybuprocaine hydrochloride) and subconjunctival anesthesia with 2% mepivacaine. (A–C) The conjunctival tumor was resected using a wide excisional biopsy with a tumor safety distance of at least 2.0 mm. (D) Cautery was gently applied to bleeding vessels. (E) The procedure of primary closure involved closure of the conjunctival defect following undermining and mobilization of the surrounding conjunctiva to cover the bare sclera. (F) The conjunctiva was then sutured by 4 interrupted 9-0 Vicryl sutures.



**Figure 3.** Shows the histopathological slides of the invasive squamous cell carcinoma of the conjunctiva stained with hematoxylin and eosin. Atypical cell nests of varying shapes infiltrating the fibrous tissue underneath the atypical superficial epithelium could be seen, which shows an altered maturation and cytologic atypia. The fibrous tissue also shows an increase in elastic fibers (solar elastosis). [(A) 50×, (B) 100×, and (C) 200× magnification]. The area selected in the black square is enlarged in the images (B) and (C).

Figure 3 shows the histopathological slides of the invasive squamous cell carcinoma of the conjunctiva stained with hematoxylin and eosin (50×, 100×, and 200× magnification). Atypical cell nests of varying shapes infiltrating the fibrous tissue underneath the atypical superficial epithelium could be seen, which shows an altered maturation and cytologic atypia. The fibrous tissue also shows an increase in elastic fibers (solar elastosis).

Written informed consent of the patient was obtained to publish this case report. In addition, this case report was approved

by the Institutional Review Board of the University of Tübingen and adhered to the tenets of the Declaration of Helsinki.

## Discussion

SSC is a curable cancer. However, misdiagnosis of this cancer can lead to a loss of time in treatment and in the worst case the progression of the disease to a life-threatening state [10].

In our case, the patient was female and of younger age (33 years old). Both is untypical for an SSC, which is more common in males [10] and in older ages [11].

Due to the unsuccessful 2-week topical therapy with Maxitrol eye drops 4 times a day before, and the described increase in size, we decided together with the patient to make 2 days later an excision without losing any further time. Loss of time may require more aggressive treatment as the tumor becomes larger and more invasive.

In recent years chemotherapy agents like MMC, interferon- $\alpha$ 2b and 5-fluorouracil are earning increasing recognition and acceptance and medical therapy has gained increasing popularity [12]. There are already initial case series describing that pure topical chemotherapy without surgery is safe and effective with complete regression in ocular surface squamous neoplasia [13].

Our experiences are in accordance with those of Sayed-Ahmed et al. [12] and Ballalai et al. [14], who reported that chemotherapy is an important tool within the treatment repertoires for the management of ocular surface squamous neoplasia. Different publications have addressed that after resection topical MMC represents a cost-effective and safe approach to minimize tumor recurrence [6–9]. Even in patients with extensive recurrent disease, topical MMC is a successful treatment for conjunctival or corneal squamous-cell carcinoma [6]. MMC is a non-cell-cycle specific alkylating agent [14]. Its mode of action mimics that of ionizing radiation.

## References:

1. Shields CL, Demirci H, Karatza E, Shields JA: Clinical survey of 1643 melanocytic and nonmelanocytic conjunctival tumors. *Ophthalmology*, 2004; 111: 1747–54
2. Gichuhi S, Mandep S, Weiss H, Burton M: Epidemiology of ocular surface squamous neoplasia in Africa. *Trop Med Int Health*, 2013; 18: 1424–43
3. Cicinelli MV, Marchese A, Bandello F, Modorati G: Clinical management of ocular surface squamous neoplasia: A review of the current evidence. *Ophthalmol Ther*, 2018; 7: 247–62
4. McKelvie PA, Daniell M, McNab A et al: Squamous cell carcinoma of the conjunctiva: A series of 26 cases. *Br J Ophthalmol*, 2002; 86: 168–73
5. Kenawy N, Garrick A, Heimann H et al: Conjunctival squamous cell neoplasia: The Liverpool Ocular Oncology Centre experience. *Graefes Arch Clin Exp Ophthalmol*, 2015; 253: 143–50
6. Shields CL, Naseripour M, Shields JA: Topical mitomycin C for extensive, recurrent conjunctival-corneal squamous cell carcinoma. *Am J Ophthalmol*, 2002; 133: 601–6
7. Russell HC, Chadha V, Lockington D, Kemp EG: Topical mitomycin C chemotherapy in the management of ocular surface neoplasia: A 10-year review of treatment outcomes and complications. *Br J Ophthalmol*, 2010; 94: 1316–21
8. Frucht-Pery J, Rozenman Y, Pe'er J: Topical mitomycin-C for partially excised conjunctival squamous cell carcinoma. *Ophthalmology*, 2002; 109: 548–52
9. Akpek EK, Ertoy D, Kalayci D, Hasiripi H: Postoperative topical mitomycin C in conjunctival squamous cell neoplasia. *Cornea*, 1999; 18: 59–62
10. Rajeh A, Barakat F, Khurma S et al: Characteristics, management, and outcome of squamous carcinoma of the conjunctiva in a single tertiary cancer center in Jordan. *Int J Ophthalmol*, 2018; 11: 1132–38
11. Gichuhi S, Sagoo MS, Weiss HA, Burton MJ: Epidemiology of ocular surface squamous neoplasia in Africa. *Trop Med Int Health*, 2013; 18: 1424–43
12. Sayed-Ahmed IO, Palioura S, Galor A, Karp CL: Diagnosis and medical management of ocular surface squamous neoplasia. *Expert Rev Ophthalmol*, 2017; 12: 11–19
13. Chaugule SS, Park J, Finger PT: Topical chemotherapy for giant ocular surface squamous neoplasia of the conjunctiva and cornea: Is surgery necessary? *Indian J Ophthalmol*, 2018; 66: 55–60
14. Ballalai PL, Erwenne CM, Martins MC et al: Long-term results of topical mitomycin C 0.02% for primary and recurrent conjunctival-corneal intraepithelial neoplasia. *Ophthalmic Plast Reconstr Surg*, 2009; 25: 296–99
15. Galor A, Karp CL, Oellers P et al: Predictors of ocular surface squamous neoplasia recurrence after excisional surgery. *Ophthalmology*, 2012; 119: 1974–81

In our case, the tumorous lesion on the nasal bulbar conjunctiva was 2.8×3.0 mm in size, appeared to be freely movable and the size progression was known. Together with the patient, we decided to remove the suspect lesion using a wide excisional biopsy with a safety distance of at least 2.0 mm. The surgical margins were diagnosed as tumor free by histopathological examination. Galor et al. showed in one of the largest studies that positive pathologic margins were one of the strongest predictors of clinical recurrence [15]. Nevertheless, treatment with topical MMC 0.02% eye drops was performed 4 times daily for 14 days. Two cycles of treatment were done with a 2-week interval during which only artificial tears eye drops were administered. At the 12-month follow-up a slit-lamp examination revealed no sign of recurrence.

## Conclusions

The primary risk factor for SCC is ultraviolet B radiation. Conjunctival SCC occurs frequently on sun exposed areas of the eye usually in sun damaged conjunctiva at the limbus. This case illustrates the effective and successful clinical management of conjunctival SSC with excision and postoperative treatment with MMC 0.02% eye drops.

## Conflicts of interest

None.