

Received: 2019.02.11
Accepted: 2019.05.14
Published: 2019.10.24

A Retrospective Study to Compare the Recurrence Rate After Treatment of Pterygium by Conjunctival Autograft, Primary Closure, and Amniotic Membrane Transplantation

Authors' Contribution:
Study Design A
Data Collection B
Statistical Analysis C
Data Interpretation D
Manuscript Preparation E
Literature Search F
Funds Collection G

ABCDEF 1 **Tobias Röck**
CDE 2 **Matthias Bramkamp**
BCDE 1 **Karl Ulrich Bartz-Schmidt**
ABCDE 1 **Daniel Röck**

1 Centre for Ophthalmology, University of Tübingen, Tübingen, Germany
2 Department of General Medicine, Ruhr-University Bochum, Bochum, Germany

Corresponding Author: Tobias Röck, e-mail: Tobias.Roeck@med.uni-tuebingen.de
Source of support: Departmental sources

Background: This study aimed to investigate the effectiveness of conjunctival autograft compared with primary closure and amniotic membrane transplantation for primary pterygium excision.





Material/Methods: Data were retrospectively studied from all primary pterygium excisions from January 2002 to December 2017 from the electronic database at the University Eye Hospital, Tübingen.

Results: From 521 primary pterygium excisions, 284 (54.5%) were primary closures, 203 (39.0%) were conjunctival autografts, and 34 (6.5%) were amniotic membrane transplants. The mean number of primary pterygium excisions was 33 per year (range, 14–56 per year). The mean patient age was 58±15 years. Younger age was associated with a significantly increased recurrence rate (P=0.002). The mean pterygium recurrence rate in the three study groups at 12 months after surgery was 11.3% (range, 6.4–14.7%). Recurrence occurred 13 patients (6.4%) in the conjunctival autograft group, 41 patients (14.4%) in the primary closure group, and five patients (14.7%) in the amniotic membrane transplantation group. Conjunctival autograft was associated with a significantly lower recurrence rate (P=0.005).

Conclusions: A retrospective study at a single center to compare conjunctival autograft with primary closure and amniotic membrane transplantation for primary pterygium excision showed a significantly lower recurrence rate after surgery using a conjunctival autograft.

MeSH Keywords: Amnion • Autografts • Biological Dressings • Conjunctiva • Pterygium • Recurrence

Full-text PDF: <https://www.medscimonit.com/abstract/index/idArt/915629>

 2304  —  3  25



Background

A pterygium is a benign degenerative and fibrovascular overgrowth of the bulbar conjunctiva onto the clear cornea that usually has a triangular shape [1]. Worldwide, the prevalence varies from 0.3–31%, and is higher in the areas near the equator [1,2]. The development of pterygia is multifactorial and includes environmental irritants, such as long-term ultraviolet-B damage, wind, dust, chemicals, air pollution, and hereditary factors. A slit-lamp examination can usually diagnose a pterygium.

Most patients who have a pterygium have few complaints from the triangular tissue of the bulbar conjunctiva; they may experience the feeling of a foreign body or that their eye looks a little different and has a cosmetic blemish when they look in the mirror. Sometimes, pterygia may become reddish in certain situations, such as dry air, lack of sleep, or exposure to smoke, wind, or dust. In most cases of pterygium, the patient wishes to have the lesion removed for cosmetic reasons, but surgery is indicated when the pterygium grows to impair vision, or reduces visual acuity by increasing astigmatism or corneal scarring.

Recently, different surgical techniques have been described in the literature for the removal of pterygia. The simplest and cheapest surgical technique is the bare sclera technique, which consists of removing the pterygium from the cornea and sclera. The sclera then heals without intervention. However, over 20 years ago, Sánchez-Thorin et al. reported in a meta-analysis that surgeons should not be encouraged to use bare sclera resection due to the higher recurrence rates of pterygia [3]. Currently, the bare sclera technique is rarely performed for the treatment of pterygium due to the high risk of recurrence, which can be as high as 88% [1,4,5]. Other surgical methods, such as primary closure, the use of a conjunctival autograft, and amniotic membrane transplantation (AMT) are promising techniques that have been associated with a lower recurrence rate [1,6].

Therefore, because of the potentially high recurrence rate of pterygium after surgical treatment, this study aimed to investigate the effectiveness of conjunctival autograft compared with primary closure and amniotic membrane transplantation for primary pterygium excision. This study included patients treated for pterygium at the University Eye Hospital of Tübingen from January 2002 to December 2017 and, to the best of our knowledge, is one of the largest retrospective studies conducted on outcome after treatment for pterygium.

Material and Methods

Data from all primary pterygium excisions performed at the University Eye Hospital, Tübingen from January 2002 to

December 2017, were retrospectively analyzed from the electronic database. The mean number of pterygium excisions and the surgical methods used, as well as the recurrence rates, were calculated and compared. This study was approved by the Institutional Review Board of the University of Tübingen and adhered to the tenets of the Declaration of Helsinki (project no. 739/2018BO2, approved on 20th Sep 2018).

Surgical methods

All surgical procedures were performed under peribulbar anesthesia.

Conjunctival autograft

The technique of conjunctival autografting involved closure of the conjunctival defect following pterygium excision with a free conjunctival autograft harvest from the supero-temporal bulbar conjunctiva. First, the head and the body of the pterygium were excised. The remaining subconjunctival degenerative part of the pterygium was excised with Westcott scissors or a hockey-stick knife. Then, polishing and smoothing of the scleral and corneal bed and limbal surfaces were performed using a motorized diamond burr. Cautery was gently applied to any bleeding vessels.

After this procedure, the residual conjunctival defect was measured with calipers. The conjunctival autograft with limbal tissue was taken from the supero-temporal bulbar conjunctiva. A sterile fine Mediware skin marker (Servoprax GmbH, Wesel, Germany) was used to outline the conjunctiva that was to be removed, according to previous measurements and the general shape of the surgical defect. The limbal edge was denoted with the skin marker so that this edge could be subsequently easily identified. Then, 2% scandicaine was injected to facilitate the separation of the conjunctiva from Tenon's capsule. The thin conjunctival autograft was then harvested by careful dissection with blunt Westcott scissors. The free conjunctival autograft was positioned over the area of the bare sclera, with care being taken to maintain the limbus-to-limbus and epithelial-side-up orientations. The autograft was sutured to the underlying sclera at the limbus and the cut conjunctiva edges by interrupted 8-0 or 9-0 vicryl sutures. The graft harvest site did not require closure as it re-epithelialized on its own.

Primary closure

The head and the body of the pterygium were excised. The remaining subconjunctival degenerative part of the pterygium was excised with Westcott scissors or a hockey-stick knife. Polishing and smoothing of the scleral, corneal bed, and limbal surfaces were performed using a motorized diamond burr. Then, the procedure of primary closure involved closure of the

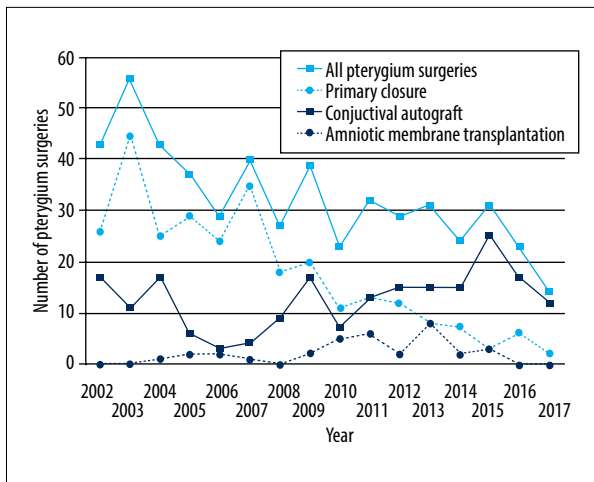


Figure 1. The distribution of all primary pterygium excisions (n=521) performed at the University Eye Hospital Tübingen between January 2002 to December 2017. The mean number of primary pterygium excisions was 33 per year (range, 14–56 per year). From 521 primary pterygium excisions, 284 (54.5%) were primary closures, 203 (39.0%) were conjunctival autografts, and 34 (6.5%) were amniotic membrane transplantations.

conjunctival defect following undermining and mobilization of the surrounding conjunctiva to cover the bare sclera. The conjunctiva was then sutured with 8-0 or 9-0 vicryl sutures.

Amniotic membrane transplantation

In this procedure, the pterygium excision and the polishing and smoothing of the scleral and corneal bed and limbal surfaces were performed, as previously described. The area of bare scleral was covered with amniotic membrane. The amniotic membrane was placed with the stromal side facing down toward the defect. The amniotic membrane was secured to the surrounding conjunctiva by interrupted 8-0 or 9-0 vicryl sutures.

Postoperative care

Following all surgical procedures, a bandage contact lens was inserted for one week to protect the cornea from trauma from the blinking eyelids. Postoperatively, artificial tears, topical steroids, and antibiotic eye drops were used, initially four times a day for two weeks. Topical steroids were tapered over 8–12 weeks depending on the degree of inflammation and the postoperative course.

Statistical analysis

Data were reported as numbers and percentages. Concerning the limited sample sizes, statistical comparisons between surgical groups were based on exact methods [7].

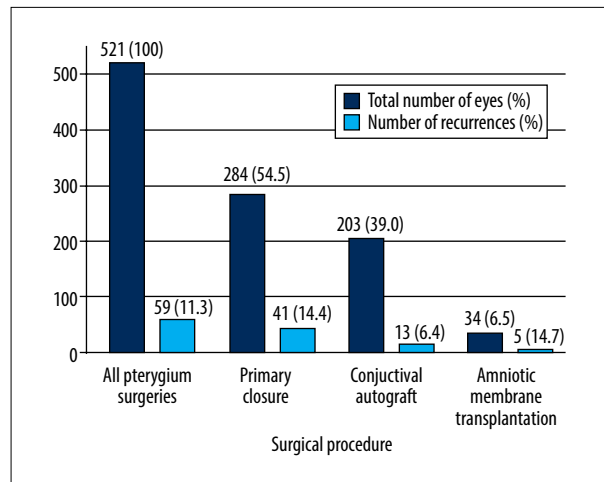


Figure 2. The recurrence rate of pterygium at 12 months after surgery. The mean pterygium recurrence rate was 11.3% and ranged from 6.4–14.7% in the three treatment groups. Recurrence occurred in 13 patients (6.4%) in the conjunctival autograft group, 41 patients (14.4%) in the primary closure group, and five patients (14.7%) in the amniotic membrane transplantation group. Conjunctival autograft was associated with a significantly lower recurrence rate ($P=0.005$).

The Fisher-Freeman-Halton exact test was performed to compare recurrence as a binary outcome across the three treatment groups, [8]. In case of a significant overall effect, post hoc between-group comparisons were performed following the closed testing procedure, and the two-tailed Fisher's exact test was used [9]. All analysis was performed using SPSS version 25.0 statistical software (IBM, Chicago, IL, USA). A P -value <0.05 was considered to be statistically significant.

Results

Between 2002 and 2017, a total of 521 primary pterygium excisions were performed at the University Eye Hospital Tübingen. From 521 primary pterygium excisions, 284 (54.5%) were primary closures, 203 (39.0%) were conjunctival autografts, and 34 (6.5%) were amniotic membrane transplants.

The mean patient age was 58 ± 15 years (range, 24–95 years). The male to female ratio was 61: 39. Figure 1 shows the distribution of all primary pterygium excisions performed at the University Eye Hospital, Tübingen by each technique. The mean number of primary pterygium excisions was 33 per year (range, 14–56 per year). There was a decreasing trend in the total number of primary pterygium excisions over the 16 years of this retrospective study. Also, the number of primary closures decreased over time. Conjunctival autografts replaced primary closures at the University Eye Hospital, Tübingen and now

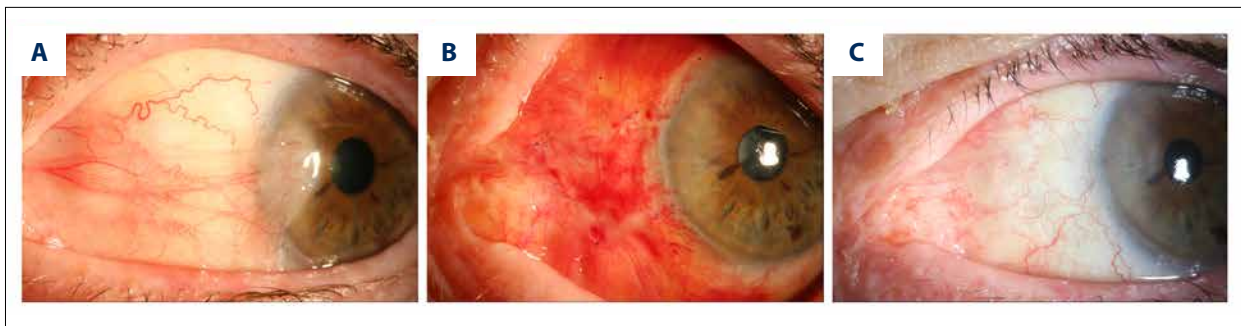


Figure 3. The appearance of the pterygium before and after surgery. (A) A slit-lamp image shows a large nasal pterygium before surgery. (B) Three days after the resection and conjunctival autograft transplantation. The conjunctival autograft was secured to the surrounding conjunctiva by interrupted 9-0 vicryl sutures. (C) A slit-lamp examination shows stable findings 12 months after surgery.

remains the preferred surgical technique for pterygium surgery, surpassing primary closure in 2012. A total of 34 pterygium excisions with amniotic membrane transplantation were performed between 2009 and 2015.

Figure 2 shows the pterygium recurrence rate at 12 months after surgery. Overall, the mean pterygium recurrence rate was 11.3% and ranged from 6.4–14.7% in the three treatment groups. Recurrence was found in 13 patients (6.4%) in the conjunctival autograft group, 41 patients (14.4%) in the primary closure group, and five patients (14.7%) in the AMT group (Figure 2).

Conjunctival autograft was associated with a significantly lower recurrence rate ($P=0.005$). Mean patient age in the recurrence group was 53 ± 12 years. Mean patient age in the group without recurrence was 59 ± 15 years ($P=0.002$). Figure 3 shows an example of the course of healing after resection and conjunctival autograft transplantation.

Discussion

The aim of this retrospective study was to compare the effectiveness of three surgical methods for primary pterygium excision that included conjunctival autograft, primary closure, and amniotic membrane transplantation for primary pterygium excision. The study was conducted at a single center, the University Eye Hospital, Tübingen during 16 years from 2002 to 2017. The findings from this study showed a significantly lower recurrence rate after surgery using a conjunctival autograft.

Surgical treatment for pterygium is not always necessary, and the ophthalmologist often uses clinical observation. Patients may find it challenging to monitor the progression of the pterygium by looking in the mirror because the pterygium is near the pupil, and growth is usually slow. Clinically it is important for patients to have a visual acuity test and a slit-lamp

examination with their ophthalmologist once a year or every other year if there is a subjective stable finding. However, if the patient notices an increase in the size of the pterygium, then they should visit the ophthalmologist earlier. Photographic documentation during a first visit is recommended and will allow comparison with findings during a subsequent follow-up visit.

Patients should be informed that ocular surface inflammation plays an important role in the growth of pterygium. Patients should also be informed that the causes of ocular surface inflammation include smoke, dry air, lack of sleep, or prolonged time in front of a computer screen. These factors affect the ocular surface and can worsen the pterygium as it becomes red and inflamed. Permanent and regular use of artificial tears several times a day may be recommended if this occurs.

Sometimes, pterygium removal may be required. Excision will be necessary when the visual acuity may be affected by an increase in the size of the pterygium and scarring of the cornea. However, the common reasons for excision are changes in visual acuity. Recently, surgical excision has been increasingly used for cosmetic reasons, resulting in increased numbers of cosmetic procedures. However, before surgery, the patient should be advised of the possibility of postoperative recurrence, which is one of the most serious complications. Recurrence is often associated with more rapid growth, including redness.

The reported rates of recurrence following surgery for pterygium in the literature have varied. Recurrence rates depend on the surgical technique [1,4,6], but also race and ethnicity of the patient. Recently, Campagna et al. showed that Hispanic and black patients are more likely to experience pterygium recurrence after amniotic membrane transplantation and conjunctival autograft [10]. Other predicting factors of recurrence are young age and ocular surface inflammation caused by environment factors [11], including dusty dry air or ultraviolet radiation [12–16]. The results of our study can confirm a young age as a significant risk factor for recurrence ($P=0.002$).

Yang et al. reported that in 97% of recurrences of pterygium, recurrence will commence within the first year following surgery [17]. Therefore, we decided to include a 12-month follow-up in the present study. In 1998 Sánchez-Thorin et al. reported that pterygium surgery without scleral recoating was inexpensive and easy to perform, but that it resulted in an unacceptably high recurrence rate [3]. In 2013, the American Academy of Ophthalmology reported that bare sclera excision of pterygium resulted in a significantly higher recurrence rate than excision accompanied by the use of conjunctival autograft [18]. Therefore, currently, the bare sclera technique is rarely performed in the treatment of pterygium [1,4,5]. Recently, different surgical procedures have been performed to try to lower recurrence rates. The main surgical methods include primary closure, conjunctival autograft, and amniotic membrane transplantation.

The findings of the present study showed a recurrence rate of 6.4% in the conjunctival autograft group, 14.4% in the primary closure group, and 14.7% in the amniotic membrane transplantation group, respectively. Conjunctival autograft was associated with a significantly lower recurrence rate ($P=0.005$). The findings of the present study are supported by the results from three previous studies that have shown recurrence rates after conjunctival autograft of 8.3%, 12.2%, and 5.4%, respectively [19–21].

We suggest taking a conjunctival limbal autograft from underneath the upper eyelid. However, if the conjunctiva underneath the upper eyelid must be preserved for future glaucoma filtering surgery, it may be advisable to use a piece of inferior conjunctiva for autografting. The second alternative would be to use amniotic membrane to fill the defect. Given the findings from other studies, in our opinion, amniotic membrane transplantation may still be reserved for cases with large conjunctival defects or insufficient conjunctiva. The amniotic membrane contains abundant growth factors, mitogenic factors,

anti-angiogenic factors, and anti-inflammatory proteins, which suppress inflammation and stimulating wound healing [22,23]. However, consistent with the findings from the present study, Clearfield et al. showed that conjunctival autograft was associated with a reduced risk of recurrence when compared with amniotic membrane transplantation [6].

However, the main challenge of conjunctival autografting is the required technical expertise of the ophthalmic surgeon and the increased operative time required due to fixation of the conjunctival autograft. Although this complication is rare, the graft can be displaced or lost. Conjunctival autografts can be fixed using different methods. Usually, absorbable 8-0 vicryl sutures or 10-0 nylon sutures are used for conjunctival autograft fixation, but fibrin glue is also an alternative.

In 1993, Cohen and McDonald first described the use of fibrin glue as a synthetic adhesive for fixation of conjunctival autografts [24]. Fibrin glue fixation requires a shorter operation time, but its main drawbacks include increased graft displacement and dehiscence. For these reasons, we prefer conjunctival autografts fixation with sutures that results in better graft stability. If the graft is fixed with sutures, they should be used only as required and not excessively, as Kumar and Singh reported that sutures are associated with postoperative discomfort, chronic inflammation, and granuloma formation [25].

Conclusions

The findings of the present study showed that pterygium surgery with conjunctival autograft was an effective method associated with a low risk of recurrence and a promising success rate.

Conflict of interest

None.

References:

- Fonseca EC, Rocha EM, Arruda GV: Comparison among adjuvant treatments for primary pterygium: A network meta-analysis. *Br J Ophthalmol*, 2018; 102(6): 748–56
- Masters JS, Harris DJ Jr: Low recurrence rate of pterygium after excision with conjunctival limbal autograft: A retrospective study with long-term follow-up. *Cornea*, 2015; 34(12): 1569–72
- Sánchez-Thorin JC, Rocha G, Yelin JB: Meta-analysis on the recurrence rates after bare sclera resection with and without mitomycin C use and conjunctival autograft placement in surgery for primary pterygium. *Br J Ophthalmol*, 1998; 82(6): 661–65
- Hirst LW: The treatment of pterygium. *Surv Ophthalmol*, 2003; 48(2): 145–80
- Rosen R: Amniotic membrane grafts to reduce pterygium recurrence. *Cornea*, 2018; 37(2): 189–93
- Clearfield E, Hawkins BS, Kuo IC: Conjunctival autograft versus amniotic membrane transplantation for treatment of pterygium: findings from a Cochrane systematic review. *Am J Ophthalmol*, 2017; 182: 8–17
- Fleiss JL: *Statistical methods for rates and proportions*. New York: Wiley, 1973
- Freeman GH, Halton JH: Note on an exact treatment of contingency, goodness of fit and other problems of significance. *Biometrika*, 1951; 38(1/2): 141–49
- Fisher RA: *Statistical methods for research workers*. Edinburgh: Oliver & Boyd, 1934
- Campagna G, Adams M, Wang L et al: Comparison of pterygium recurrence rates among different races and ethnicities after primary pterygium excision by surgeons in training. *Cornea*, 2018; 37(2): 199–204
- Kim KW, Kim JC: Current approaches and future directions in the management of pterygium. *Int J Ophthalmol*, 2018; 11(5): 709–11
- Coroneo MT: Pterygium as an early indicator of ultraviolet insolation: A hypothesis. *Br J Ophthalmol*, 1993; 77(11): 734–39
- Hilgers JH: Pterygium: Its incidence, heredity and etiology. *Am J Ophthalmol*, 1960; 50(4): 635–44

14. Marchetti C, Sidahmed-Adrar N, Collin F et al: Melatonin protects PLPC liposomes and LDL towards radical-induced oxidation. *J Pineal Res*, 2011; 51(3): 286–96
15. Kau HC, Tsai CC, Lee CF et al: Increased oxidative DNA damage, 8-hydroxydeoxy-guanosine, in human pterygium. *Eye*, 2006; 20(7): 826–31
16. Balci M, Sahin S, Mutlu FM et al: Investigation of oxidative stress in pterygium tissue. *Mol Vis*, 2011; 17: 443–47
17. Yang Y, Pi M, Xu F: Observation of long-term efficacy of corneal limbal conjunctival autografts in microscopy treatments of pterygium. *Eye Sci*, 2013; 28: 73–78
18. Kaufman SC, Jacobs DS, Lee WB et al: Options and adjuvants in surgery for pterygium: A report by the American Academy of Ophthalmology. *Ophthalmology*, 2013; 120(1): 201–8
19. Fernandes M, Sangwan VS, Bansal AK et al: Outcome of pterygium surgery: Analysis over 14 years. *Eye*, 2005; 19(11): 1182–90
20. Ma DH, See LC, Liau SB et al: Amniotic membrane graft for primary pterygium: Comparison with conjunctival autograft and topical mitomycin C treatment. *Br J Ophthalmol*, 2000; 84(9): 973–78
21. Al Fayed MF: Limbal versus conjunctival autograft transplantation for advanced and recurrent pterygium. *Ophthalmology*, 2002; 109(9): 1752–55
22. Röck T, Bartz-Schmidt KU, Landenberger J et al: Amniotic membrane transplantation in reconstructive and regenerative ophthalmology. *Ann Transplant*, 2018; 23: 160–65
23. Nuzzi R, Tridico F: How to minimize pterygium recurrence rates: Clinical perspectives. *Clin Ophthalmol*, 2018; 12: 2347–62
24. Cohen RA, McDonald MB: Fixation of conjunctival autografts with an organic tissue adhesive. *Arch Ophthalmol*, 1993; 111(9): 1167–68
25. Kumar S, Singh R: Pterygium excision and conjunctival autograft: A comparative study of techniques. *Oman J Ophthalmol*, 2018; 11(2): 124–28