

Received: 2017.05.25

Accepted: 2017.07.19

Published: 2017.12.15

The Evolution of Corneal Transplantation

Authors' Contribution:
Study Design A
Data Collection B
Statistical Analysis C
Data Interpretation D
Manuscript Preparation E
Literature Search F
Funds Collection G

ABCDEF 1 **Tobias Röck**
DEF 1 **Johanna Landenberger**
CDEF 2 **Matthias Bramkamp**
ACDEF 1 **Karl Ulrich Bartz-Schmidt**
ABCDEF 1 **Daniel Röck**

1 Centre for Ophthalmology, University of Tübingen, Tübingen, Germany
2 Department of General Medicine, Ruhr-University Bochum, Bochum, Germany

Corresponding Author: Tobias Röck, e-mail: Tobias.Roeck@med.uni-tuebingen.de

Source of support: Departmental sources

Background: The aim of this study was to investigate the evolution of surgical methods in and leading indications for corneal transplantation from 2005 to 2016.

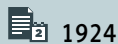
Material/Methods: Data from the corneal graft waiting list and from all keratoplasties carried out between 2005 and 2016 at the University Eye Hospital Tübingen were retrospectively evaluated.

Results: A total of 1259 keratoplasties were performed between 2005 and 2016 at the University Eye Hospital Tübingen. The most common surgical indications for corneal transplantation were Fuchs endothelial corneal dystrophy (45.5%) and keratoconus (14.2%). The mean rate of corneal transplantations almost doubled from 71 keratoplasties per year in the first 6-year period to 139 keratoplasties per year in the second 6-year period ($P=0.005$). The number of penetrating keratoplasties remained similar. The number of Descemet membrane endothelial keratoplasties (DMEK) increased significantly from 2008 to 2016 ($P<0.0001$). One DMEK procedure was performed in 2008 (representing 1.4% of all transplantations), while 75 DMEK procedures were performed in 2016 (representing 60.5% of all transplantations) ($P<0.0001$). DMEK became the favored surgical method for endothelial disorders, exceeding penetrating keratoplasty in 2013.

Conclusions: Our study shows evolutionary changes in preferred corneal transplantation techniques and leading indications for keratoplasty from 2005 to 2016. Since its introduction a decade ago, DMEK is currently the golden standard in the management of corneal endothelial dysfunction.

MeSH Keywords: **Corneal Transplantation • Descemet Membrane • Descemet Stripping Endothelial Keratoplasty • Keratoplasty, Penetrating**

Full-text PDF: <https://www.annalsoftransplantation.com/abstract/index/idArt/905498>



1924



3



26



Background

Eduard Zirm performed the first successful corneal transplantation in 1905 [1]. It is still the most frequent type of transplantation performed in humans [2]. After Zirm's milestone in 1905, only a few improvements were made over the next 100 years, involving microscopes, sutures, antibiotics, and corticosteroids, but there was little change in the surgical techniques used. However, the first decade of the 21st century saw an explosion in more selective endothelial replacement techniques [3].

In recent years, the improvements in corneal transplantation techniques have revolutionized corneal transplant surgery. The breakthrough occurred in 2006, when Melles et al. successfully introduced a new technique for transplanting isolated Descemet's membrane (DM) through a self-sealing tunnel incision, which they referred to as DM endothelial keratoplasty (DMEK) [3].

In the years before DMEK was first described, different new lamellar keratoplasty techniques have been reported, including Descemet stripping endothelial keratoplasty (DSEK) [4] and Descemet stripping automated endothelial keratoplasty (DSAEK) [5]. These procedures, especially DMEK [3,6], provide various benefits over penetrating keratoplasty (PK), based on its minimal invasiveness, low rate of rejection, and minimal refractive shift, with very quick visual improvement [7].

In 2006, Darlington et al. performed a review of corneal transplantation, analyzing data from 1980 to 2004 [8]. They found that more than 95% of corneal tissues were used for PK, and the major indications were pseudophakic bullous keratopathy, keratoconus, Fuchs endothelial dystrophy (Fuchs' dystrophy), and repeat grafts.

Confronted with the new possibilities of lamellar keratoplasty and inspired by the investigation of Darlington et al. [8], we decided to investigate the changes in surgical methods, the statistics on keratoplasties, and leading indications at the University Eye Hospital Tübingen from 2005 to 2016.

Material and Methods

The medical history of all keratoplasties performed between January 2005 and December 2016 at the University Eye Hospital Tübingen were retrospectively analyzed. The indications for transplantation were categorized according to keratoconus, Fuchs' dystrophy, bullous keratopathy, trauma, rejection, and others. The number of keratoplasties was determined annually. The yearly numbers of performed keratoplasties were evaluated on the basis of the surgical method [PK, DSAEK, DMEK,

Deep anterior lamellar keratoplasty (DALK, and Boston keratoprosthesis]. Figure 1 shows a schematic overview displaying: (A) a virgin cornea and (B–F) different keratoplasty procedures: (B) PK, (C) Boston keratoprosthesis, (D) DALK, (E) DSAEK, and (F) DMEK.

The indications for corneal transplantation were obtained from the waiting list at the turn of the respective year. This study was approved by the Institutional Review Board of the University of Tübingen and adhered to the tenets of the Declaration of Helsinki.

Statistical analysis

Statistical analysis of the data was conducted using the Statistical Packages for the Social Sciences (SPSS 18.0). Quantitative variables are expressed as mean \pm standard deviation (SD). $P < 0.05$ was considered to be statistically significant. Descriptive statistics and graphic representations of the trend of transplantation techniques and indications were prepared. Yearly rates of corneal transplantation were compared using the *t* test.

Results

Between 2005 and 2016, 1259 corneal transplantations were performed at the University Eye Hospital Tübingen. These included 725 (57.6%) PKs and 534 (42.4%) lamellar keratoplasties (LKs). The mean rate of keratoplasties almost doubled from 71 corneal transplantations per year in the first 6-year period to 139 corneal transplantations per year in the second 6-year period ($P = 0.005$).

Surgical technique

Between 2005 and 2016, the annual numbers of PK remained similar. Between 2005 and 2007, keratoplasty was only carried out in the form of PKs. The first endothelial keratoplasty (EK) was carried out in 2008 using the DSAEK method. Exclusively, 20 DSAEK procedures were carried out from 2008 to 2009. DMEK quickly replaced DSAEK at the University Eye Hospital Tübingen and remained the favored EK technique until now. One DMEK procedure was carried out in 2008 (representing 1.4% of all keratoplasties), while 75 DMEKs were carried out in 2016 (representing 60.5% of all keratoplasties) ($P < 0.0001$). DMEK became the favored surgical method for endothelial disorders, exceeding penetrating keratoplasty in 2013. Boston keratoprosthesis, DALK, and DSAEK were performed in small numbers during the 12-year period, representing 0.3%, 1.8%, and 1.6% of the total keratoplasties, respectively.

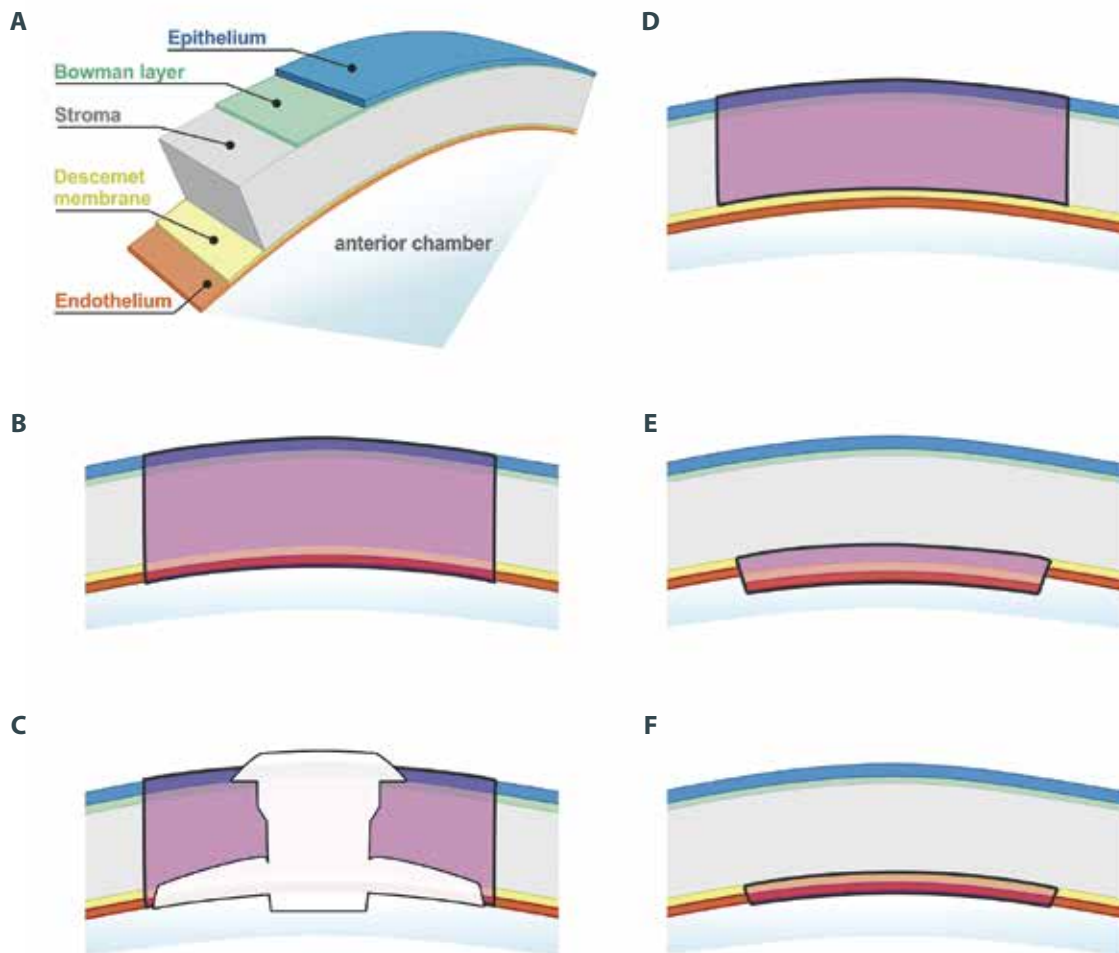


Figure 1. Schematic overview displaying: (A) a virgin cornea and (B–F) different keratoplasty procedures: (B) PK, (C) Boston keratoprosthesis, (D) DALK, (E) DSAEK, and (F) DMEK.

Figure 2 shows the distribution of corneal transplantations by technique (PK, DSAEK, DMEK, DALK, and Boston keratoprosthesis) of the 1259 performed keratoplasties from 2005 to 2016.

Indications for corneal transplantation

The indications for corneal transplantation were obtained from the waiting list, which increased from 36 patients in 2005 to 246 patients in 2016. During the study period, the leading surgical indications for keratoplasties were Fuchs' dystrophy (45.5%) and keratoconus (14.2%). Other indications for corneal transplantation were bullous keratopathy (10.4%), trauma (4.3%), rejection (8.9%), and others such as bacterial, fungal, viral or *Acanthamoeba keratitis*, and penetrating corneal ulcers due to trophic disease or chemical and thermal burns of the cornea (16.8%). In 2005, keratoconus was the most common indication (41.7%) for corneal transplantation, but in 2016 it was only the third most common (6.5%). Since 2013, the rate of Fuchs' dystrophy as a surgical indication for corneal transplantation

increased significantly ($P < 0.0001$). Fuchs' dystrophy was the leading surgical indication for keratoplasty from 2010 to 2016. In 2005, Fuchs' dystrophy was only the fourth most common indication (8.3%) for corneal transplantation, but in 2016 it was the most common (69.5%).

Figure 3 shows the distribution of the corneal graft waiting list with indications (Fuchs' dystrophy, keratoconus, bullous keratopathy, trauma, rejection, and others) for corneal transplantation at the turn of the year from 2005 to 2016 in 936 cases.

Discussion

Our study shows the changing trends in corneal transplantation methods and leading indications for corneal transplantation at the University Eye Hospital in Tübingen from 2005 to 2016.

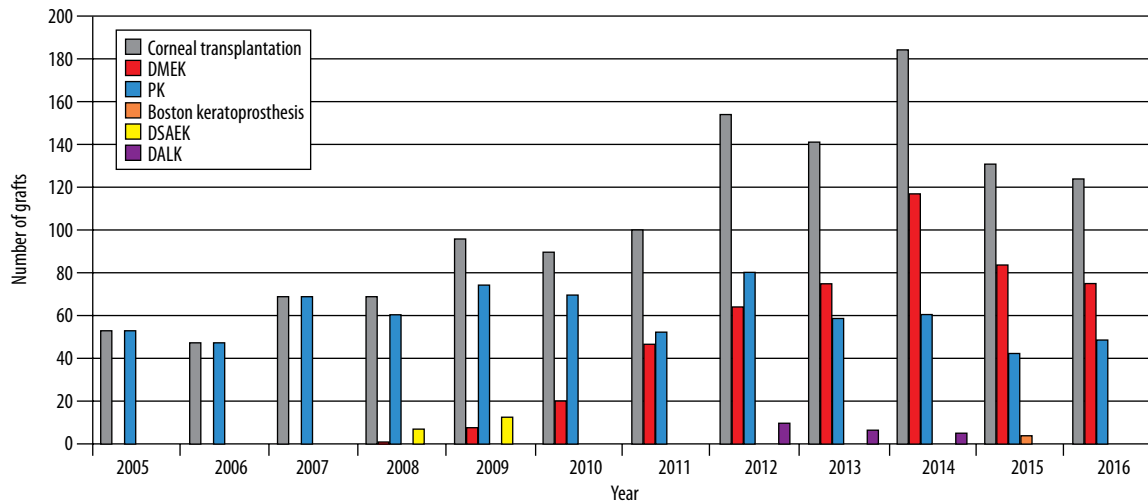


Figure 2. This figure shows the distribution of corneal transplantations by technique (PK, DSAEK, DMEK, DALK, and Boston keratoprosthesis) of the 1259 keratoplasties performed from 2005 to 2016. Between 2005 and 2007, corneal transplantation was exclusively performed in the form of PK. The first endothelial keratoplasty (EK) was performed in 2008 using the DSAEK technique. DMEK quickly replaced DSAEK at the University Eye Hospital Tübingen and became and remains the preferred surgical technique for endothelial diseases, surpassing penetrating keratoplasty in 2013. DMEK increased significantly from 2008 to 2016 ($P < 0.0001$).

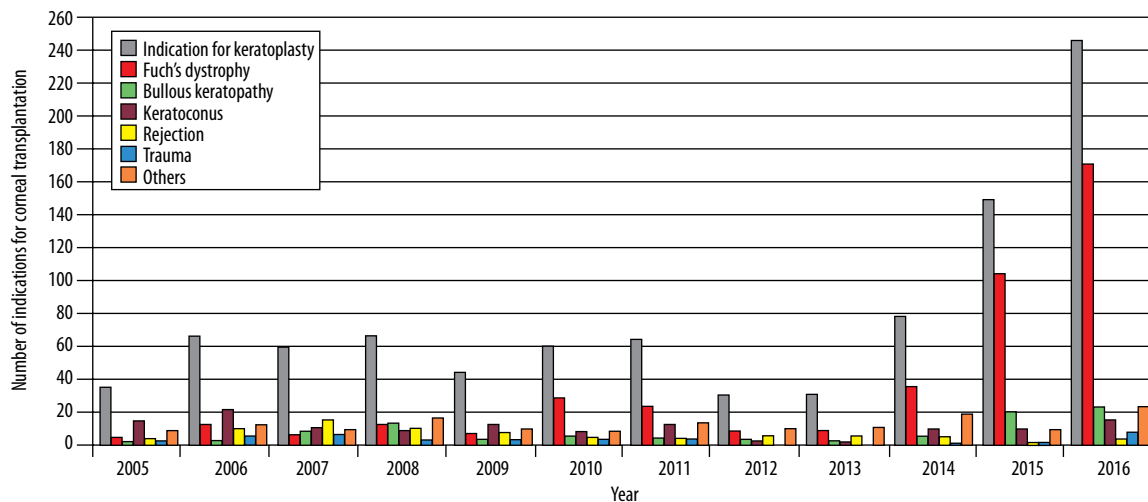


Figure 3. This figure shows the distribution of the corneal graft waiting list with indications (Fuchs' dystrophy, keratoconus, Bullous Keratopathy, trauma, rejection, and others) for corneal transplantation at the turn of the year from 2005 to 2016 in 936 cases. The leading surgical indications for corneal transplantation were Fuchs' dystrophy (45.5%) and keratoconus (14.2%) throughout the study period. Since 2013, the rate of Fuchs' dystrophy as a surgical indication for corneal transplantation increased significantly ($P < 0.0001$).

The most common surgical indications for corneal transplantation were Fuchs' dystrophy and keratoconus. These leading common surgical indications were almost equal to the main indications for corneal transplantation reported in previous studies [9–13]. The sequence of indications changes by country and depends on environmental causes and the surgeon.

Our study documented that the rate of keratoplasties almost doubled from 71 corneal transplantations per year in the first 6-year period to 139 corneal transplantations per year in the second 6-year period. The reasons for the increase are demographic changes, changes in surgical procedures (especially endothelial procedures), and the increase of corneal donors, at the University Hospital in Tübingen.

Between 2005 and 2007, keratoplasty was only carried out in the form of PK. However, EK has evolved dramatically into an alternative to PK in cases of compromised endothelial cell layer without irreversible stromal damage. Consequently, EK has replaced PK in the treatment of endothelial dysfunctions to a great extent all over the world. The first EK was performed in our center in 2008 using the DSAEK method. Only 20 DSAEK procedures were carried out from 2008 to 2009. DMEK quickly replaced DSAEK at the University Eye Hospital Tübingen and remains the favored EK technique to manage endothelial cell disorders. DMEK is well-established and was first reported in 2006 by Melles [3,6], providing various advantages over PK based on its minimal invasiveness, lower intraoperative risks, and minimal refractive shift with very fast visual recovery [10,14,15]. One DMEK procedure was carried out in 2008 (representing 1.4% of all keratoplasties), while 75 DMEK procedures were performed in 2016 (representing 60.5% of all transplantations) ($P < 0.0001$). DMEK surgery is very complicated, presenting the challenges of stripping the donor graft and then manipulating it. Implementing and processing the stripped 15- μm -thin Descemet membrane is a huge challenge. The stripped Descemet membrane rolls in automatically, showing the endothelial layer on the outside. After injection into the anterior chamber, the main challenges are rolling it out, identifying which side shows the endothelial layer, and positioning it centrally without folds. All these difficult procedures have to be carried out without touching the Descemet membrane.

Improvements in microsurgical techniques like the EK procedure and the enormous success of the DMEK have allowed many more patients with endothelial disorders to undergo keratoplasties earlier than before. Corneas that had been considered to be too early for PK are now qualified for DMEK. This is in contrast to 2006, when Afshari et al. reported that almost no eyes with Fuchs' dystrophy and a visual acuity more excellent than 0.5 qualified for a keratoplasty [16].

However, the surgical center needs a specialist surgeon who feels comfortable with the DMEK procedure, which requires a sophisticated technique. There is the possibility that surgeons are afraid to change, for example from DSAEK to DMEK, when graft reserve is lacking, due to the higher hazard of graft preparation failure and consequent graft waste when starting to use this novel method. Fortunately, this has not been the case in our hospital due to our own in-house eye bank and excellent surgeons. One more obstacle and main intraoperative complication, especially for novice DMEK surgeons, is difficulty in graft unfolding.

Maier et al. and our study group reported in 2015 that an important factor for the outcome of the DMEK surgery for patients with endothelial disorders is not waiting too long for surgery [17,18]. Our study group showed a relationship between the outcome of the DMEK surgery with disease severity [18]. With the advances in EK, the patients receive and also require the corneal transplantation surgery earlier, if corneal tissue is available. Better visual acuity also corresponds to a higher quality of life. For these reasons, pressure on eye banks to procure more suitable corneal grafts has been growing enormously in recent years.

Although DALK was already described in 2002 [19], it was carried out in our hospital in small numbers during the 12-year study period, representing 1.8% of the total corneal grafts. The moderate introduction of DALK is probably due to its longer surgical time with the big bubble technique, a higher technical challenge, the introduction of collagen crosslinking in patients with progressive keratoconus [20], a lower number of patients with the indication for DALK, and, consequently, a slower and more difficult learning curve for the surgeon.

Corneal graft scarcity is a common dilemma over most of the world. As already mentioned above, it consists of a growing need for corneal grafts as a result of demographic changes on the one hand, and the growing number of surgical procedures, especially endothelial ones, on the other hand [6]. In Germany, recent years have been challenging regarding corneal donors after publicity about various transplantation scandals [21,22]. The public has suffered a massive lack of confidence in the transplantation system. The loss of trust has influenced the donation rate significantly [22]. Furthermore, the acquisition of donor corneas is based on sufficient staff levels of the eye bank team [23], increasing public education of people about corneal donation [24], and a working system of connections between intensive care units and the responsible eye bank colleagues [25].

Furthermore, the knowledge and awareness of corneal donation through education is important to meet the corneal scarcity and gain more corneal donors to help our visually impaired

patients in sufficient numbers with corneal transplantations. For these reasons, researchers are concerned and try to combat the scarcity of corneal tissue. Yoeruek et Bartz-Schmidt described a novel approach to decrease the shortage of corneal tissue. A solution for the future could be to split the stripped Descemet membrane lamellae (split-DMEK) for 2 recipients and use the denuded anterior part for DALK of a third recipient [26]. This technique could help 3 recipients to have restored vision.

References:

- Zirm E: Eine erfolgreiche totale Keratoplastik. *Graefes Arch Ophthalmol*, 1906; 64: 580–93 [in German]
- Gain P, Jullienne R, He Z et al: Global survey of corneal transplantation and eye banking. *JAMA Ophthalmol*, 2016; 134: 167–73
- Melles GR: Posterior lamellar keratoplasty: DLEK to DSEK to DMEK. *Cornea*, 2006; 25: 879–81
- Price FW Jr., Price MO: Descemet's stripping with endothelial keratoplasty in 50 eyes: A refractive neutral corneal transplant. *J Refract Surg*, 2005; 21: 339–45
- Gorovoy MS: Descemet-stripping automated endothelial keratoplasty. *Cornea*, 2006; 25: 886–89
- Melles GR, Ong TS, Ververs B et al: Descemet membrane endothelial keratoplasty (DMEK). *Cornea*, 2006; 25: 987–90
- Guerra FP, Anshu A, Price MO: Descemet's membrane endothelial keratoplasty: Prospective study of 1-year visual outcomes, graft survival, and endothelial cell loss. *Ophthalmology*, 2011; 118: 2368–73
- Darlington JK, Adrean SD, Schwab IR: Trends of penetrating keratoplasty in the United States from 1980 to 2004. *Ophthalmology*, 2006; 113: 2171–75
- Boimer C, Lee K, Sharpen L et al: Evolving surgical techniques of and indications for corneal transplantation in Ontario from 2000 to 2009. *Can J Ophthalmol*, 2011; 46: 360–66
- Fasolo A, Frigo AC, Böhm E et al: The CORTES study: Corneal transplant indications and graft survival in an Italian cohort of patients. *Cornea*, 2006; 25: 507–15
- Cunningham WJ, Brookes NH, Twohill HC et al: Trends in the distribution of donor corneal tissue and indications for corneal transplantation: The New Zealand National Eye Bank Study 2000–2009. *Clin Exp Ophthalmol*, 2012; 40: 141–47
- Ting DS, Sau CY, Srinivasan S et al: Changing trends in keratoplasty in the West of Scotland: A 10-year review. *Br J Ophthalmol*, 2012; 96: 405–8
- Robert MC, Choronzey ME, Lapointe J et al: Evolution of corneal transplantation in the province of Quebec from 2000 to 2011. *Cornea*, 2015; 34: 880–87
- Cursiefen C, Küchle M, Naumann GO: Changing indications of penetrating keratoplasty: Histopathology of 1,250 corneal buttons. *Cornea*, 1998; 17: 468–70
- Terry MA, Ousley PJ: Deep lamellar endothelial keratoplasty visual acuity, astigmatism, and endothelial survival in a large prospective series. *Ophthalmology*, 2005; 112: 1541–48
- Afshari NA, Pittard AB, Siddiqui A et al: Clinical study of Fuchs corneal endothelial dystrophy leading to penetrating keratoplasty: A 30-year experience. *Arch Ophthalmol* 2006; 124: 777–80
- Maier AK, Gundlach E, Schroeter J et al: Influence of the difficulty of graft unfolding and attachment on the outcome in Descemet membrane endothelial keratoplasty. *Graefes Arch Clin Exp Ophthalmol*, 2015; 253: 895–900
- Röck T, Bramkamp M, Bartz-Schmidt KU et al: Causes that influence the detachment rate after Descemet membrane endothelial keratoplasty. *Graefes Arch Clin Exp Ophthalmol* 2015; 253: 2217–22
- Anwar M, Teichmann KD: Big-bubble technique to bare Descemet's membrane in anterior lamellar keratoplasty. *J Cataract Refract Surg*, 2002; 28: 398–403
- Raiskup-Wolf F, Hoyer A, Spoerl E et al: Collagen crosslinking with riboflavin and ultraviolet-A light in keratoconus: long-term results. *J Cataract Refract Surg*, 2008; 34: 796–801
- Röck T, Bramkamp M, Bartz-Schmidt KU et al: Organ transplantation scandal influencing corneal donation rate. *Int J Ophthalmol*, 2017; 10: 1001–3
- Röck D, Petersen P, Yoeruek E et al: Effect of organ scandal on corneal donation rate and organ donors at a German University Hospital. *Ann Transplant*, 2017; 22: 425–30
- Röck D, Bartz-Schmidt KU, Röck T: Rates of and experiences with corneal donation at the University Hospital Tübingen from 2002 to 2015. *Ann Transplant*, 2016; 21: 433–38
- Röck D, Wude H, Yoeruek E et al: Evaluation of factors limiting corneal donation. *Ann Transplant*, 2016; 21: 701–7
- Röck T, Hofmann J, Thaler S et al: Factors that influence the suitability of human organ-cultured corneas. *Graefes Arch Clin Exp Ophthalmol*, 2016; 254: 135–41
- Yoeruek E, Bartz Schmidt KU: Current approaches to combat the shortage of corneal tissues: Split-DMEK and double-split keratoplasty. *Cornea*, 2015; 34: e6–9

Conclusions

Our study showed evolutionary changes in preferred corneal transplantation techniques and leading indications for keratoplasty from 2005 to 2016. Since its introduction a decade ago, DMEK is currently the golden standard in the management of corneal endothelial dysfunction.